The Aqualift®

Water-Jet Assisted Dissection (Hydrodissection) as a Basic Concept for a Gentle Facelift

Thomas Tork M.D. – www.dr-tork.de

Summary

Facelifts carried out using hydrodissection (Aqualift®) are a particularly gentle version of SMAS lifting in which water-jet assisted preparation (hydrodissection) is used.

While the SMAS lift (superficial musculoaponeurotic system) is a method that 'resets the clock' in a particularly natural way by lifting and repositioning the connective tissue and muscular structures, the author has refined this method over several years of clinical experience during his training in cosmetic plastic surgery under Professor Ivo Pitanguy in Rio de Janeiro and the renowned plastic surgeon Professor Bruce Connell in Santa Ana, California, and supplemented it with the methods of water-jet assisted liposuction (WAL) and particularly hydrodissection. This particularly gentle method, which is known as Aqualift®, includes the preparation of the anatomical structures using water-jet assisted dissection (body-jet®). The procedure described facilitates one of the crucial steps of a facelift with a gentle and efficient dissection while minimising secondary damage.

The dissection of the mandibular ligaments and the zygomatic ligaments is an important prerequisite for tension-free repositioning of the SMAS and subsequently of the superior cutaneous structures. Both are necessary to achieve a natural lasting result. The precise and gentle hydrodissection using WAL is a valuable tool in this regard.

Positive effects on the smoothing of nasolabial folds and on the lifting and tightening of the chin line, for example, are already apparent during surgery. The result is a more alert, livelier expression around the eyes and a completely natural overall appearance.

.Introduction

The desire to develop efficient but gentle techniques with lasting results to rejuvenate the human appearance is the motivation behind the research and trialling of a number of new methods that all share a common goal: achieving better results compared to conventional and more laborious procedures with considerably less downtime, risk and discomfort.

The Aqualift® hydrodissection method presented here is not a completely new technique but is rather an expanded concept to facilitate one of the most important steps during the facelift, the dissection. The water-jet assisted preparation method ensures high tissue selectivity with efficient and gentle dissection associated with minimal secondary damage.

Procedure

Throughout its historical development, water-jet assisted technology has always been used in situations where the gentle preparation of the target structure with the least possible irritation of the surrounding vessels, nerves and connective tissue aggregate is of the highest priority.

Furthermore, depending on the shape and pressure of the water-jet, it is also possible to detach firm structures such as scar tissue and to separate accretions and adhesions while minimising trauma.
In the lower half of the face and the chin/neck transition area, such adhesions and ligamentous structures lead to the formation of marionette lines and subsequently the development of the typical pouching on the cheek soft tissues due to the effects of gravity.

In many cases, the signs of ageing are also associated with the development of a double chin, which can be treated at the same time using a combined water-jet suction and dissection cannula instead of a dissection cannula alone.

In rather slim patients with a thin neck and mobile cervical skin structures, thinning out a moderate submental fat deposit using liposuction is avoided as a rule. In these patients, liposhifting is achieved by mobilising the fat cells which contributes to a younger appearance by filling out the ventral cervical skin areas.
Incorporating the water-jet technology (body-jet® device) for hydrodissection has the following benefits for a facelift:

- gentle but efficient dissection
- tissue-selective dissection
- rapid, safe and versatile applications.

Using the WAL cannula (human med AG) with flat jet nozzle and a diameter of 2.4 mm it is possible to safely detach adhesions without trauma. Using fan-shaped movements while constantly controlling the level of dissection with the guiding hand, the mobilisation is done using the criss-cross technique.

There is solid evidence that water-jet technology is gentle and e.g. reduces the development of haematomas and postoperative swelling caused by the release of histamines. There is a significant reduction in the need for electrocautery for haemostasis. Vacuum drainage can be omitted. An additional indicator is the rapid healing process and the comple-

Figure 1: Patient preoperative and 2 weeks postoperative following a facelift with waterjet-assisted dissection

Figure 2: WAL flat angle (180°) water-jet cannula 2.4 mm

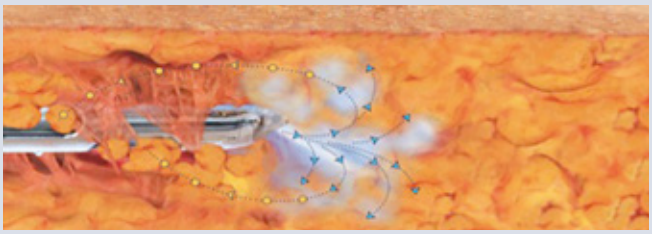

Figure 3: body-jet© WAL cannula with the fan-shaped water-jet: simultaneous water-jet infiltration and fat aspiration

Figure 4: body-jet© evo

Figure 5: body-jet©

tely natural appearance of the postoperative flexibility and mobility of the cheek structures.

Adequate mobilisation is achieved when uniform mobility of the tissue can be seen to the tip of the chin when moderate tension is applied to the skin of the cheek parallel to the line of the chin. In particular, adhesions lying above the jaw bone between the jaw and the corners of the mouth can be easily mobilised with a very noticeable effect.

In contrast, with the conventional technique, there is a considerable degree of tissue trauma with the classic clinical features such as swelling and haematomas being almost impossible to avoid.

Using the narrow flat angle WAL cannula of 2.4 mm (see Figure 2) and the pulsating water-jet of the body-jet®, tissue dissection can be very well controlled and ensures safe operation by constantly assessing the preparation depth using the guiding hand. A combination with other surgical methods such as blepharoplasty or expansion of the facelift and combination with a forehead/eyebrow lift are also options as is the combination with water-jetassisted liposuction (WAL) in the chin area.

Figures 6-8: Hydrodissection with body-jet® 2.4 mm flat jet WAL cannula

Only after the mobilisation is completed by turning the water-jet in a cranial direction and mobilising the preauricular area up to the temporal region, the actual typical preauricular incision with a classic facelift is carried out in what is now a particularly gentle procedure on the basis of the extensive and atraumatic dissection that has already been performed with the water-jet.

Surgical method

Following photo-documentation and precise planning of the surgery incorporating older photo-documentation and the impressions of the individual dynamics of the face of the patient and the specific wishes obtained during consultations, the procedure is performed under general anaesthesia or deep sedation under supervision and anaesthetic management by an experienced anaesthetist.

Nasal intubation is preferred so that the mouth region is left as natural as possible.

Starting from three stab incisions below the earlobes and the tip of the chin ventral to the typical submental folds, the first step in the Aqualift® is hydrodissection with the body-jet® using the 2.4 mm diameter flat jet WAL cannula that enables mobilisation of the entire area ventral to the anterior edge of the sternocleidomastoid muscle to the chin tip and the middle of the lower lip. In doing so, the typical submental folds are also mobilised as are the mandibular ligament structures which lead to the development of 'jowls' along with the effects of gravity.

Figures 9-10: Carrying out the facelift with very little or no use of electrocautery; nasal intubation if possible

Here it is left to the personal preferences of the surgeon whether he or she works with preparation and rotation of an SMAS flap or plication of the SMAS. Regardless, all possible procedures benefit from the atraumatic hydrodissection that enables the surgeon to work almost entirely without the use of electrocautery for haemostasis. Resection of the skin is done after marking using a Pitanguy marker and enables tension-free adaptation of the edges of the skin. The slight postoperative swelling and the equally moderate haematoma formation attest to the gentle action of the Aqualift© technique.

Only just a few days after surgery the patient is able to return to 'normal' life. On day 8 after surgery, the suture material is removed and systematic sun protection is necessary for the scar tissue that is still reddened at this point.

Figures 11-12: Patient before surgery and 5 days after surgery

Figures 13-15: Patient before surgery and 5 days and 3 weeks after surgery

Conclusion

On the journey to preserving physical allure and in particular a youthful appearance for the face in a manner that is as simple and tolerable as possible, the concept behind the Aqualift© of using water-jet assisted liposuction and hydrodissection with the body-jet® can further improve outcomes. The typical risks such as postoperative bleeding and nerve lesions or irritations are much reduced.

Certainly, it cannot be considered any more than adding another piece to the mosaic; the surgeon and particularly the patient benefit from the facilitation of routine surgical practice that assures trouble-free wound healing with proper application.

Literature

1 Connell BF. Neck contour deformities. The Art, Engineering, Anatomic Dagnosis, Architectural Planing and Aesthetics of Surgical Correction Clinics in Plastic Surgery – Vol. 14, No. 4, Okctober 1987

2 Connell BF. Finess in Rhytidectomy. Recent Advances in Plastic Surgery, No. 3, New York, Churchill Livingstone 1985, pp. 137-154

3 Piek J, Wille Ch, Warzok R, Gaab MR. Waterjet Dissection of the Brain – experimantal and first clinical Results. J Neurosurg 89: 861-864

4 Siegert R. Wasserstrahldissektion in der Medizin, Focus Mul 18, Heft 2, 2001, Weismann PA. Simplified Technique in Submental Lipectomy. Plast. reconst. Surg. 48: 443-446, 1981

5 Ueberreiter K et al. BEAULI ™ – eine neue Methode zur einfachen und zuverlässigen Fettzell-Transplantation. Handchir Mikrochir Plast Chir 2010; 42: 379 - 385.

human med AG
Wilhelm-Hennemann-Str. 9 • 19061 Schwerin • Germany
Phone: +49 (385) 395700 • Fax: +49 (385) 3957029 • info@humanmed.com

© human med AG 01/2016 • REF 9001077 • Editor: Inge Matthiesen, Ph.D.

www.humanmed.com

human med®